

## SHORT HISTORY OF MAMMOGRAPHY: A BELGIAN PERSPECTIVE

A. Van Steen<sup>1</sup>, R. Van Tiggelen<sup>2</sup>

**It took the surgery community more than half a century to accept mammography. Three periods can be observed in the history of the evolution of mammography. The first one goes from 1913 to 1940, the second one from 1940 to 1970, and the third period from 1970 to the end of the century, when a high quality of mammography with an even lower dose is achieved by digital systems for both diagnostic and screening purpose.**

**Key-words:** Breast, radiography – Radiology and radiologists, history.

The first attempts to use radiography for the diagnosis of breast abnormalities were made in the late 1920's, but mammography, as we understand it nowadays, using dedicated X-ray units, was developed in the 60s.

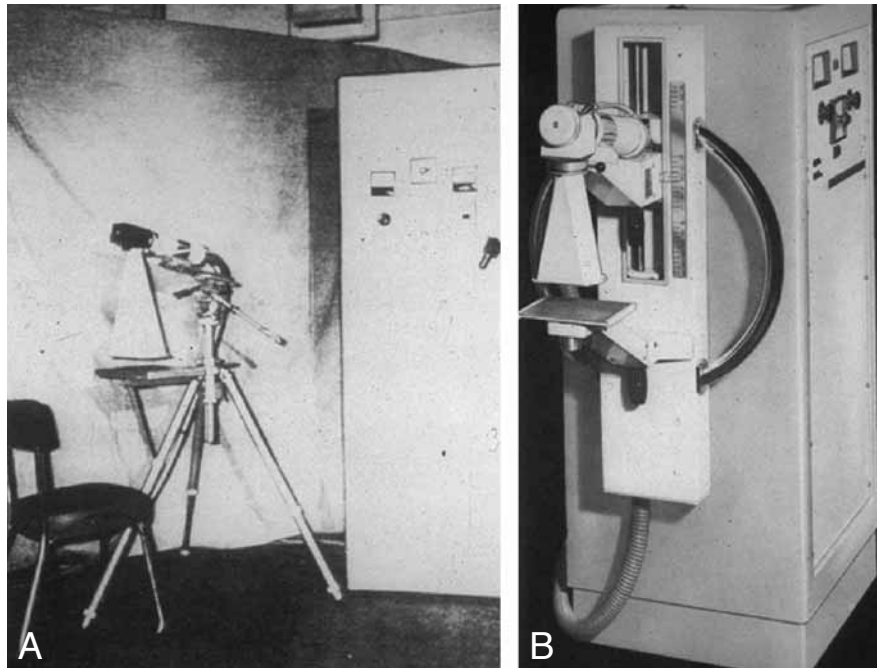
In this contribution, we briefly overview three major periods in the history of mammography. The first period starts in 1913 with the observations of a German surgeon, laying the foundation for mammography. From 1940 to around 1970 followed the development of the technique by radiologists and later by the industry, and the last quarter of the 20<sup>th</sup> century was dominated by the arrival of breast cancer screening, the use of ultrasound and magnetic resonance imaging and nowadays the transition to digital mammography systems.

We can observe three periods in the history of the evolution of mammography.

### **The first period goes from 1913 until 1940**

This period is characterised by the originality of the important contributions of a surgeon of Berlin, A. Salomon (1913) (1). The originality resides in the anatomo-radiological confrontation of 3000 mastectomy pieces. The foundations of mammography reside in the confrontation of this first time semiology of macroscopic anatomy with microscopic examinations.

During one quarter of a century, some publications report on the tryout to apply this method to the radiology of the breast. Among others, the work of the German doctors O. Kleinschmidt (1927) (2) and W. Vogel (1930) (3), the work of the Spanish J. Goyanes et al. (1929) (4), and that of S.L. Warren (5) and



*Fig. 1. — A. First Sénographe – constructed by Ch. Gros. B. First mammography machine by CGR.*

Gershon-Cohen (1937) (6) in the USA. The latter one further explored this field and published a renowned textbook in the sixties (7).

### **The second period extends from 1940 until 1970**

It is an auspicious period for the confirmation of mammography. Nevertheless, it must be emphasized that the method, as a result of research done by a surgeon, has been refuted by the surgery community, even when the reliability and the quality of the images were unquestionable when the method was used in conformity of the indications given by the pioneers.

R. Leborgne, living in Montevideo, devoted to mammography since 1940, provides us with the essential data of this technique and the interpretation of the images (8).

During this period, each publication on breast radiology, either by the didactic quality or by personal observations on the technique, equipment or choice of film, contributed something to the development of mammography.

It is important to emphasize the preponderant position taken, in France, from the 60s on, by F.B. Baclesse and A. Willemin in Paris (9) and by Ch. Gros (10) in Strasbourg, not to forget R. Egan (1964) (11) in the USA. We will not go into details of the technical aspects ("cooking recipes" well-known by the specialists), but we find it opportune to mention that the French words

*From:* 1. Department of Radiology, University Hospitals Leuven, Leuven, 2. Belgian Museum for Radiology, Brussels, Belgium.

*Address for correspondence:* Dr A. Van Steen, Department of Radiology, KU Leuven, Herestraat 49, B-3000 Leuven, Belgium. E-mail: andre.vansteen@uz.kuleuven.ac.be

"sénologues" and "sénologie" were a legacy of Ch. Gros, who trained many Belgian radiologists.

On the other hand, we can not hide the importance of the participation of radiological industry to the development of mammography. Under impulse of Ch. Gros, from 1965 on, the "Compagnie Générale de Radiologie (CGR)" started to build the "Sénographe" (Fig. 1). Ch. Gros, not forgetting he was also a physicist, worked out this apparatus designed for imaging the breast, equipped with a special molybdenum anode which has a spectrum especially for soft tissue radiographies. As the first builder of this type of equipment, by 1970 CGR had sold around 2000 Senographs throughout the world, of which many in Belgium.

In the meantime, the film industry becomes devoted to improve the quality of the sensitive layer and to extend the possibility to vary the contrast and to improve the examination of mammal glands of young women. Their contribution was also essential to respond to the concern of reducing the radiation doses.

The marketing of mammography equipment in 1967 induces a revolution in breast imaging. Previously an ordinary X-ray tube was used for bone radiography, and the radiological film (low sensitive industrial film) was placed directly under the skin of the breast, with consequently a high exposure to X-rays.

### The third period covers the last quarter of the 20<sup>th</sup> century

Indeed, from 1970, it is suggested to name mammography the most appropriate technique for breast cancer screening. One of the pioneers was undoubtedly Ph. Strax in the United States with his study called Health Insurance Plan (HIP) of NY, a first report about reduction of mortality by mammography (12). In Europe, we have L. Tabar from Sweden and P. Dean from Finland (13) who examined over 130.000 patients.

Women undergoing a mammography mainly did so for evaluation of a discovered nodule. A fine needle puncture (FNAC) of the nodule was performed, to retrieve some cells for analysis (14). Often this procedure provided no diagnostic information, especially in the case of benign lesions. In most cases, the diagnosis was provided by surgical resection of the nodule, fortunately often benign.

Since the start of the programme "Europe against Cancer" of the European Union in 1987, we observe a generalisation of the screening campaigns, and through an increased control, a homogeneity and higher quality of mammography (15).

Today, the perfection of the mammography equipment, films and even the technique and procedure of imaging, results in a high quality radiological image of the breast with an exposure about 10 times lower than 30 years ago.

Mid seventies, ephemeral techniques such as thermography and xerography appeared for a short period (16).

In the late 70s, sonography of the breast is developed, and progressively becomes complementary to mammography, without the possibility to replace mammography since micro calcifications – sometimes the only indication of a developing cancer- can not be detected by ultrasound. However, this technique is still used, and is becoming an essential part in the further appointment of a clinical-mammographic discovered lesion.

By the end of the 80s, next to sonography, magnetic resonance imaging (MRI) of the breast becomes important as an additional examination technique to mammography, although MRI is clearly more expensive and unable to detect micro calcification. This technique is primarily used for specific problems we will not cover here (17).

Introduced about 10 years ago, digital mammography nowadays is in full expansion (18, 19). Reducing the dose even further, this digital method offers an image richer in contrast, with a quality approaching film-screen capability in detection of details. The major advantage resides in the digitalisation, so the image and its magnification can be changed, a rapid transfer can be made between stations ("Telemammography") and a copy can be archived for future comparison. Digital images also allow creation of databanks.

Ongoing research shows potential for development of digital mammography; screen-film mammography alone no longer represents the best quality of diagnostic imaging service for patients requiring mammography. Further development of the digital mammography should give rise to new techniques such as CAD and tomosynthesis in the future.

### Conclusion

It took the surgery community more than half a century to accept mammography. From the 60's on, French, Swedish and North-American radiologists made mammography a well-established technique, and the radiological industry developed dedicated apparatus with a special anode increasing contrast and lowering radiation dose to the breast.

Nowadays a high quality of mammography with an even lower dose is achieved by digital systems, to the benefit of women, for both diagnostic and screening purpose.

### Bibliography

1. Salomon A.: Beiträge zur Pathologie und Klinik der Mammakarzinome. *Arch Klin Chir*, 1913, 101: 573-668.
2. Kleinschmidt O.: Brustdrüse. In: Die Klinik der bösartigen Geschwülste. Zweife P., Payr E., Hirzel S. Leipzig, 1927, pp 5-90.
3. Vogel W.: Die Röntgendarstellung der Mammatumoren. *Arch Klin Chir*, 1932, 171: 618-626.
4. Goyanes J., Gentil D.F., Guedes B.: Sobre la radiografía de la glándula mamaria y su valor diagnóstico. *Arch Españ de Oncologica*, 1931, 2: 111-142.
5. Warren S.L.: A roentgenologic study of the breast. *AJR*, 1930, 24:113-124.
6. Gershon-Cohen J., Colcher A.E.: Evaluation of roentgen diagnosis of early carcinoma of breast. *JAMA*, 1937, 108: 867-871.
7. Gershon-Cohen J.: Atlas of mammography. Springer-Verlag, Berlin, New-York, Heidelberg, 1970.
8. Leborgne R.: The breast in roentgen diagnosis. Impressora Uruguay, Montevideo 1953.
9. Baclesse F., Willemin A.: Atlas de mammographie. Librairie de la Faculté des Sciences, Paris, 1965.
10. Gros Ch.: Les maladies du sein. Masson, Paris, 1963.
11. Egan R.: Mammography Thomas, Chicago, 1964.
12. Tabár L., Dean P.: Teaching atlas of mammography. 2nd ed. Thieme Verlag, New-York, 1985.
13. Dodd G.D., Fry K., Delany W.: Pre-op localization of occult carcinoma of the breast. In: Nealon T.F., ed. Management of the patient with breast cancer. Saunders, Philadelphia, 1965, 88-113.
14. Zoetelief J., Fitzgerald M., Leitz W., Säbel M.: European protocol on dosimetry in mammography. European Commission, 1996.
15. Gould H.R., Ruzicka F.F., Sanchez R., et al.: Xeroradiography of the breast. *AJR*, 1960, 84: 220-223.
16. EL Youssef S.J., Alfidí R.J., Duscheneau R.H., et al.: Initial experience with nuclear magnetic reso-

- nance (NMR) imaging of the human breast. *J Comput Assist Tomogr*, 1983, 7: 215-218.
17. Freedman M.T., Pe E., Zuurbier R., et al.: Image processing in digital mammography. In: Kim Y (ed). Proc SPIE Image Capture, Formatting and Display 2164. Bellingham, Washington: Soc Photo-Optical Instr Engs, 1993, 537-554.
18. Strax Ph., Venet L.: Value of mammography in reduction of mortality from breast cancer in men screening. *ASR*, 1973, 117: 686-689.
19. Jong R.A., Jaffe M.J.: Digital mammography: 2005. *Can Assoc Radiol J*, 2005, 319-323.
-